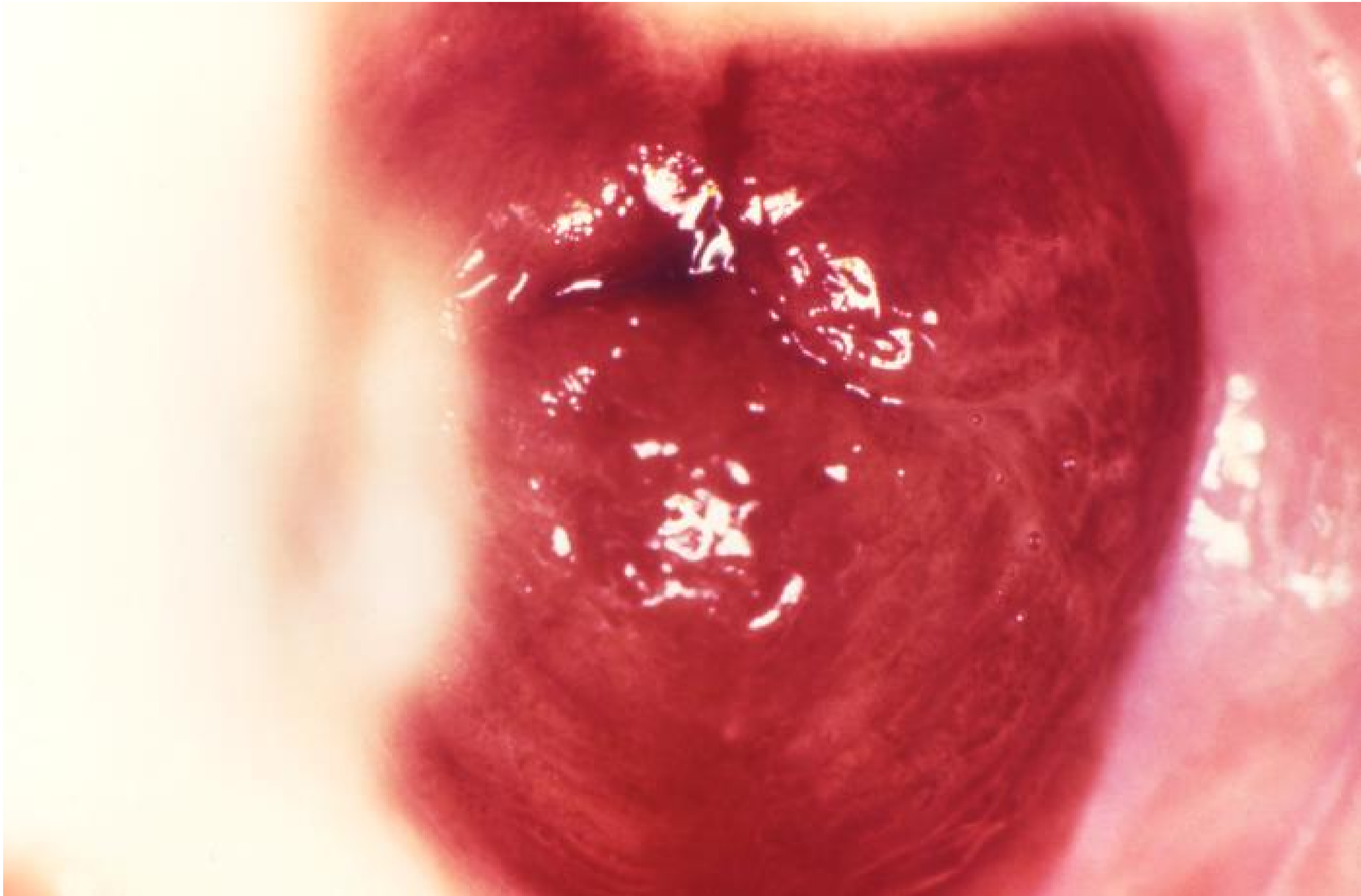


[Back to Search Results](#)


ID#:	19143
Description:	<p>Caption: This image depicts a close colposcopic view of a cervix, in the case of a patient, who had presented to a clinical setting exhibiting a condition known as cervicitis, in inflammation of the cervix. Note the reddened appearance of the cervical mucosa surrounding the cervical os, or the cervical opening, and the dilated mucosal blood vessels in the region. The cause of this inflammation was not given.</p>
High Resolution:	Click here for hi-resolution image (18.34 MB)
Content Providers(s):	CDC/ Dr. Wiesner
Creation Date:	1972
Photo Credit:	
Links:	

Categories:

CDC Organization

↳

MeSH

↳ Anatomy

↳ Urogenital System

↳ Genitalia

↳ Genitalia, Female

↳ Uterus

↳ Cervix Uteri

↳ Diseases

↳ Female Genital Diseases and Pregnancy Complications

↳ Genital Diseases, Female

↳ Uterine Diseases

↳ Cervix Diseases

↳ Cervicitis

Copyright Restrictions:

None - This image is in the public domain and thus free of any copyright restrictions.

Add to My Pictures

[Back to Search Results](#)